




Bringing Volunteer Medical & Dental Care to Children in Need

 [fb.com/Ecuadent](https://www.facebook.com/Ecuadent)

 [@EcuadentConnect](https://twitter.com/EcuadentConnect)

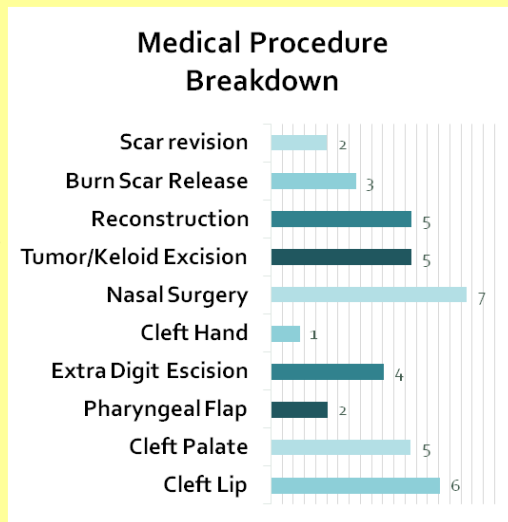
Celebrating 25 Years of service in Ecuador!

Spring 2016

Medical Mission

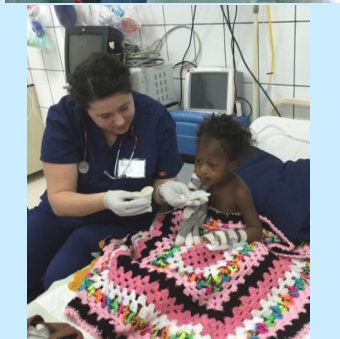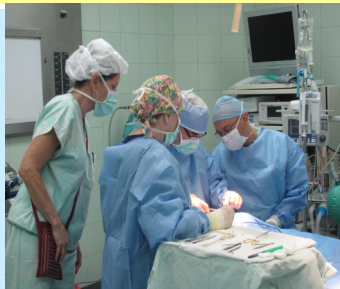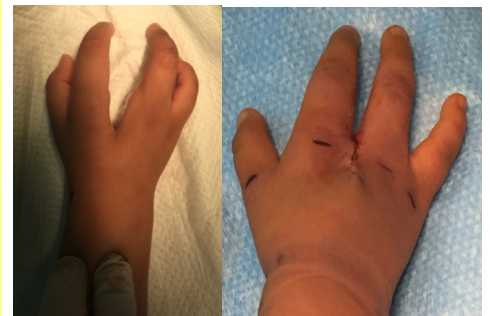February 18-27, 2016

The Medical Team traveled to Esmeraldas to complete one day of triage and four days of surgery. After triaging 93 patients and determining severity of the malformations and their effects on the patients' health, Ecuadent selected 40 patients to treat. This year 25% of cases were lip and palate corrections, which is an increase from past missions.



Matthews Valdivieso

Matthews, age 2, and his family traveled 8 hours from Guayaquil to Esmeraldas for Ecuadent to repair his cleft hand. Without repair, Matthews would have trouble writing, grasping toys, and picking up utensils for eating. Thanks to the help of the Ecuadent Medical team, Matthews' hand was repaired and he can enjoy all the fun of being a toddler.



Radiology Mission

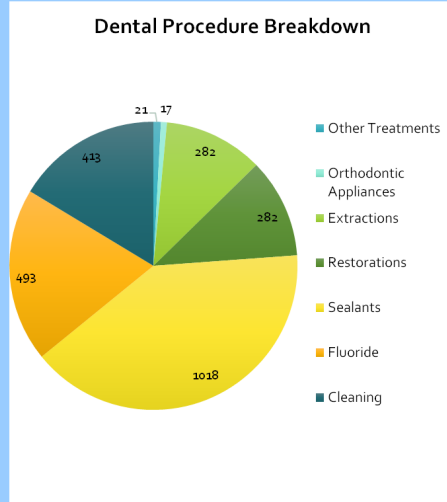
February 25- March 5, 2016

Dartmouth Hitchcock Radiology teamed up with Ecuadent for a second year to provide diagnostic radiology services and education in the Guayaquil Navy Hospital. With a team of two staff radiologists, one body image fellow, and two senior residents, the team was able to provide 15 hours of formal lecture to hospital radiology and emergency medicine staff. The team also provided interpretation and assessment of 108 different exams and data scans. Through lectures and clinical training, Dartmouth and Ecuadent are working towards continuing the development of the Ecuadorian health workforce.

Dental Mission

February 25- March 5, 2016

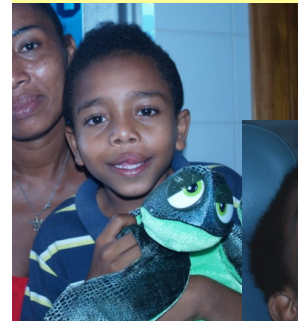The Dental Team ventured to Salinas to complete five days of dental treatment. The team treated 595 patients and completed 2,614 procedures, as well as 17 appliances. Thanks to countless donations, Ecuadent gave out over 1,000 toothbrushes, toothpaste, and floss to children and families who came to see us. We are grateful for the help of the Ecuadorian Red Cross who sent over twenty volunteers to assist with translation during the dental mission.



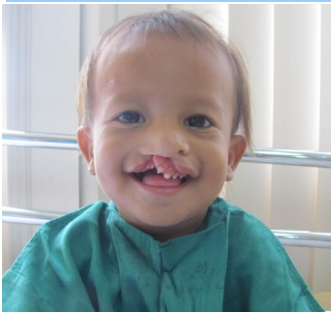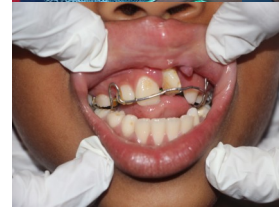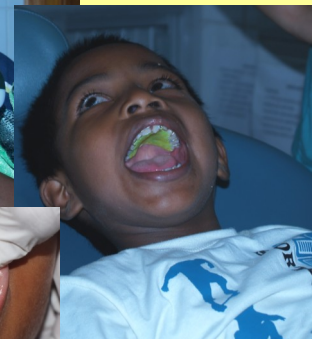Ronald Mina and Luis Campos

Two patients Ronald (age 9) and Luis (age 7) had crooked front teeth from cleft palate surgery when they were younger. They traveled from Esmeraldas to Salinas for the Dental Mission where Dr. Robert Scott made appliances to straighten out their teeth. Dr. Scott met with the boys, made their appliances and took careful measures to ensure the parents understood how the device worked. Both boys are on their way to straighter teeth!

Ronald Mina



Luis Campos



Thank You
to our 2016
Mission Donors!



Interested in joining the Ecuadent Team? Contact the office or visit us online to learn how!

